

Role, safety, and efficacy of WEB flow disruption: a review

EJMINT Invited Review, 2014: 1419000139 (8th May 2014)

Laurent Pierot, Anil Gholkar, Laurent Spelle, Thomas Liebig, Christophe Cognard, István Szikora

Abstract

For many years, endovascular treatment has been the first line treatment for both ruptured and unruptured aneurysms. [1-4] However aneurysms with a complex anatomy (fusiform aneurysms, wide-neck aneurysms, large and giant aneurysms) are in some cases untreatable or difficult to treat with standard coiling. For this reason, more complex endovascular techniques have been developed, such as balloon-assisted coiling, stent-assisted coiling, and flow diversion.

Keywords: aneurysms, endovascular treatment, flow disruption, WEB

Introduction

For many years, endovascular treatment has been the first line treatment for both ruptured and unruptured aneurysms [1-4]. However, aneurysms with a complex anatomy (fusiform aneurysms, wide-neck aneurysms, large and giant aneurysms) are in some cases untreatable or difficult to treat with standard coiling. For this reason, more complex endovascular techniques have been developed, such as balloon-assisted coiling, stent-assisted coiling and flow diversion [5].

Wide-neck aneurysms present challenges for coiling since stabilisation of coils in the aneurysm presents the potential risk of protrusion of coils in the parent vessel. Balloon-assisted coiling, stent-assisted coiling and the use of flow diverters have all increased the number of wide-neck aneurysms that may be treated using an endovascular technique, especially in aneurysms having a sidewall (lateral) geometry [5-9]. For the treatment of wide-neck aneurysms located at bifurcations, compliant balloon- or double balloon-assisted coiling can be used as well as Y stenting [10]. These methods are frequently technically difficult and their use remains relatively limited. The use of intra-luminal flow diverters does not, with few exceptions, address aneurysms of this type, as it is not always possible to cover completely the neck singularly when it involves two branches of the bifurcation. Also, as the flow diverter has to be placed in one branch of the bifurcation, the flow in other branches can be compromised. Moreover, while balloon-assisted coiling may be used in both ruptured and unruptured aneurysms, the use of stent-assisted coiling and intravascular flow diversion is essentially limited to unruptured aneurysms due to the need of dual antiplatelet treatment.

Role, safety, and efficacy of WEB flow disruption: a review

Laurent Pierot (Corresponding Author) – Department of Neuroradiology, Hôpital Maison-Blanche, University Reims-Champagne-Ardenne, Reims, France Email: lpierot@gmail.com

Anil Gholkar – Department of Neuroradiology, Royal Victoria Infirmary, Newcastle, United Kingdom

Laurent Spelle – Department of Neuroradiology, Hôpital Beaujon, Assistance Publique-Hôpitaux de Paris, Clichy, France

Thomas Liebig – Department of Neuroradiology, Universitaetsklinikum Koeln, Cologne, Germany

Christophe Cognard – Department of Neuroradiology, Purpan Hospital, University of Toulouse, France

Istvan Szikora – Department of Neurointerventions, National Institute of Clinical Neurosciences, Budapest, Hungary

The concept of intrasaccular flow disruption

Flow disruption is an innovative technique utilising an intra-aneurysmal device placed inside the aneurysm sac at the level of the neck to disrupt the intra-aneurysmal flow and subsequently create intra-aneurysmal (and intra-device) thrombosis. The surface exposed at the level of the neck is smooth, providing good support for the development of neointima.

The WEB family (Figure 1)

Several WEB devices are now available for aneurysm treatment: WEB-DL, WEB-SL and WEB-SLS.

The WEB-DL is composed of an inner and outer nitinol braid held together by proximal, middle and distal radio-opaque markers, and creates two compartments: one distal and one proximal. The WEB-SL and WEB-SLS are single-layer devices with 2 different shapes: barrel shape for the WEB-SL (similar to WEB-DL) and spherical shape for the WEB-SLS.

Recently, EV (enhanced visualisation) versions of these devices were developed with the introduction of platinum filaments to improve visualisation of the devices during treatment.

The WEB implants are deployed similarly to endovascular coil systems through microcatheters with an internal diameter $> 0.027''$. The detachment system is electrothermal and instantaneous. The WEB-DL, SL and SLS received CE Mark for unruptured and ruptured aneurysms as well as EV versions.

Procedural modalities with WEB

The treatment of aneurysms with WEB is completed using similar techniques such as those used in the treatment of aneurysms with coils (e.g. general anesthesia, intraoperative treatment with intravenous heparin, single or double femoral approach). Single or dual antiplatelet treatment is not necessary for WEB treatment, and pre-, intra- and post-operative antiplatelet therapies are managed as indicated for typical endovascular treatment with coils. As stent-assisted coiling is frequently a potential alternative treatment in case of unruptured aneurysms, single- or dual-antiplatelet premedication is frequently used in this situation.

Accurate evaluation of aneurysm anatomy (aneurysm morphology, aneurysm transverse diameter and height and neck size) using magnetic resonance imaging (MRA), 2D and 3D-digital subtraction angiography (DSA) is necessary to determine the feasibility of treatment with the WEB and also the appropriate device sizing. Sizing is an important part of the procedure. Undersizing of the device will be associated with potentially insufficient coverage of the aneurysm neck leading to incomplete aneurysm treatment. On the other hand, if the device is oversized, there is no risk of pressure against the aneurysm wall (as the radial force is very low), but there is a risk of protrusion of the device into the parent vessel. The sizing recommendation is to average the available aneurysm widths and heights and select a WEB that is 1 mm greater than the average width and 1 mm smaller than the average/minimum height. The WEB can be placed at the neck of the aneurysm and, if it does not fill the entire aneurysm volume (i.e., blebs or fundus), the implant still provides effective contrast stasis and eventual thrombosis in those distal areas and the aneurysm overall.

The triaxial technique (long introducer sheath / distal access catheter / microcatheter) is currently used for the WEB treatment. After positioning the distal access catheter into the internal carotid artery (ICA) or vertebral artery (VA), the aneurysm is catheterised with dedicated VIA and VIA Plus microcatheters (Sequent Medical) according to the size of the device to be deployed in the aneurysm. The WEB device (WEB-DL, WEB-SL or WEB-SLS) is chosen according to aneurysm measurements and is then deployed in the aneurysmal sac. Control DSA is performed to check the position of the device in the aneurysm and to evaluate flow stagnation inside the aneurysm. Dyna-CT is also helpful to analyse the position of the device in the aneurysm [11]. If the position is unsatisfactory, the device is resheathed and repositioned. If the size is not appropriate, the device is resheathed and another device is deployed into the aneurysm. When the right-sized device is correctly positioned, a final DSA run is performed. Treatment with ancillary devices (balloon, coils and stent) can be performed if deemed necessary by the treating physician. In recently published series (Table 1), additional treatment was performed in 10.5 % to 23.8 % of cases.

Table 1 Clinical and anatomical results in the series of the literature

Clinical Results (Table 1)

Several series have been published in the literature regarding WEB Flow Disruption [12-15].

These series clearly show that the most frequent indications for WEB treatment are wide-neck (66.7 % to 100.0 %) bifurcation aneurysms. In order of frequency, the most common aneurysmal locations treated with WEB are middle cerebral artery, basilar artery, anterior communicating artery and ICA (Figures 2-4).

The feasibility of the treatment is high (92.8 % to 100.0 %) showing that despite the fact that a large microcatheter is necessary for this type of treatment, WEB results are as successful as standard coiling. Failures were mostly encountered during initial experience with the device and were related to difficulties related to microcatheterisation or inappropriate sizing.

Despite the very specific population (wide-neck bifurcation aneurysms) and the fact that the series includes the first cases treated with this new technique (i.e., learning curve), the rate of adverse events is low. In the larger series (French series), intra-operative complications occurred in 13.0 % of patients. This rate is similar to what was observed in ATENA (13.4 %) and CLARITY (17.0 %) [15-16]. Intraoperative rupture occurred in 1.3 % of patients during the treatment of a ruptured aneurysm. This rate is slightly lower compared to ATENA (2.6 %) and CLARITY (3.7 %). Thromboembolic events occurred in 11.7 % of patients, which is also similar to what is reported in ATENA (7.1 %) and CLARITY (13.3 %). Most of these thromboembolic events were “appearance of thrombus” during the procedure, which were successfully treated with IA or IV antiplatelet medications.

Finally, the mortality was 0.0 % in all series and morbidity was between 1.3 % and 5.3 %. These results are similar to what was reported in large series with standard endovascular treatment. Morbidity and mortality were respectively 1.7 % and 1.4 % in ATENA and 3.7 % and 1.5 % in CLARITY.

Anatomical results (Table 1)

In the 4 series reported with the WEB device, only mid-term anatomical results were evaluated and not in all patients. The rate of adequate occlusion (total occlusion or neck remnant) was high, between 80 and 92.9 %. In all these series, a relatively high rate of neck remnant was depicted. Careful analysis showed that some of them were in fact an opacification of the proximal recess of the device and not a true neck remnant. However, the stability of this aspect was not analysed.

In a recent multicentre European series collecting the first 45 cases treated with WEB, an experienced interventional neuroradiologist independently evaluated anatomical results [17]. At short-term anatomical follow-up (6 months), complete aneurysm occlusion was obtained in 24.3 % of patients, opacification of the proximal recess with complete occlusion of the aneurysm in 32.4 % of aneurysms, neck remnant in 24.3 % of aneurysms and aneurysm remnant in 18.9 % of patients. Adequate occlusion (complete occlusion, opacification of the proximal recess or neck remnant) was observed in 81.1 % of aneurysms post-procedure. At mid-term anatomical follow-up (13 months), complete aneurysm occlusion was observed in 27.6 % of aneurysms, opacification of the proximal recess with complete occlusion of the aneurysm in 41.4 % of aneurysms, neck remnant in 20.7 % of aneurysms and aneurysm remnant in 10.3 % of aneurysms. Adequate occlusion was observed in 89.7 % of aneurysms evaluated at longest follow-up.

Evolution between short-term and midterm follow-up was also analysed. In 92.9 % of aneurysms, aneurysm occlusion was stable. In 7.1 %, a worsening of the aneurysm occlusion was observed in midterm follow-up. Importantly, all aneurysms with opacification of the proximal recess at 3 - 6 months short-term follow-up had a stable aneurysm occlusion at midterm follow-up.

These results are quite satisfactory knowing that wide neck is an important factor affecting the quality of aneurysm occlusion at mid-term [18].

Clinical trials

Two prospective, multicentre clinical trials have been conducted in Europe (WEBCAST) and France (French Observatory). Enrolment is now completed with 51 patients in WEBCAST and 62 patients in French Observatory. Safety and efficacy data are currently under analysis and will be presented and published in the next few months.

Conclusion

WEB Flow Disruption is a new, innovative endovascular technique dedicated to the treatment of ruptured and unruptured wide-neck bifurcation aneurysms. Initial clinical experience has shown high feasibility of the treatment with good safety profile (no mortality and low morbidity). The efficacy has still to be precisely analysed with evaluation of long-term stability of the treatment, but initial results are promising at 13 months.

WEB Flow Disruption offers a new option for the treatment of complex wide-neck bifurcation aneurysms and, potentially with the new single layer WEBs, additional aneurysms.

Conflict of interest

LP consults for Sequent. LS, TL and CC proctor for Sequent.

References

1. Molyneux A, Kerr R, Stratton I, et al, International Subarachnoid Aneurysm Trial (ISAT) Colaborative Group. International Subarachnoid Aneurysm Trial (ISAT) of neurosurgical clipping versus endovascular coiling in 2143 patients with ruptured intracranial aneurysms: a randomised trial. *Lancet*. 2002; 360:1262-1263.
2. Mc Dougall CG, Spetzler RF, Zabramski JM, et al. The Barrow Ruptured Aneurysm Trial. *J Neurosurg*. 2012; 116:135-144.
3. Cognard C, Pierot L, Anxionnat R, et al. Results of embolization used as the first treatment choice in a consecutive non selected population of ruptured aneurysms: clinical results of the Clarity GDC study. *Neurosurgery*. 2011; 69: 837-841.
4. Pierot L, Spelle L, Vitry F, for the ATENA investigators. Clinical outcome of patients harbouring unruptured intracranial aneurysms treated by endovascular approach: results of the ATENA trial. *Stroke*. 2008; 39: 2497-2504.
5. Pierot L, Wakhloo A. Endovascular treatment of intracranial aneurysms: current status. *Stroke*. 2013; 44: 2046-2054.
6. Pierot L, Spelle L, Leclerc X, et al. Endovascular treatment of Unruptured Intracranial Aneurysms: Comparison of Safety of remodeling technique and standard treatment with coils. *Radiology*. 2009, 251: 846-855.
7. Pierot L, Cognard C, Anxionnat R, et al. The remodelling technique for endovascular treatment of ruptured intracranial aneurysms had a higher rate of adequate occlusion than did conventional coil embolization with comparable safety. *Radiology*. 2011, 258: 546-553.
8. Pierot L, Cognard C, Spelle L, et al. Safety and efficacy of balloon remodelling technique during endovascular treatment of intracranial aneurysms: Critical review of the literature. *AJNR Am J Neuroradiol*. 2012; 33:12-15.
9. Pierot L. Flow diverters stents in the treatment of intracranial aneurysms: Where are we? *J Neuroradiol*. 2011;38 :40-46.
10. Spiotta AM, Gupta R, Fiorella D, et al. Mid-term results of endovascular coiling of wide-necked aneurysms using double stents in a Y configuration. *Neurosurgery*. 2011; 69: 421-429.
11. Caroff J, Mihalea C, Neki H, et al. Role of C-Arm VasoCT in the Use of Endovascular WEB Flow Disruption in Intracranial Aneurysm Treatment. *AJNR Am J Neuroradiol*. (in press)
12. Pierot L, MD, Liebig T, Sychra V, et al. Flow disruption : a new endovascular approach for the treatment of intracranial aneurysms. Results of a preliminary, multicenter series. *AJNR Am J Neuroradiol*. 2012; 33: 1232-1238.

13. Lubicz B, Mine B, Collignon L, et al. WEB device for endovascular treatment of wide-necked bifurcation aneurysms. *AJNR Am J Neuroradiol*. 2013; 34: 1209-1214.
14. Pierot L, Klisch J, Cognard C, et al. Endovascular flow disruption in middle cerebral artery aneurysms: preliminary feasibility, clinical and anatomical results in a multicenter study. *Neurosurgery*. 2013; 73: 27-34.
15. Papagiannaki C, Spelle L, Januel AC, et al. Intracapsular flow disruption with WEB-DL device: report of a prospective series of 83 patients with 85 aneurysms. *AJNR Am J Neuroradiol* (in press)
16. Pierot L, Cognard C, Ricolfi F, et al on behalf of CLARITY group. Mid-term anatomical results after endovascular treatment of ruptured intracranial aneurysms with GDC™ and Matrix™ coils: analysis of the CLARITY series. *AJNR Am J Neuroradiol*. 2012; 33: 469-473.
17. Lubicz B, Klisch J, Gauvrit JY, et al. Short-term and mid-term follow-ups in patients with wide-neck bifurcation aneurysms treated with the WEB device: a retrospective European study. *AJNR Am J Neuroradiol*. 2014; 35: 432-438.
18. Pierot L, Cognard C, Anxionnat R, et al for the CLARITY investigators. Endovascular treatment of ruptured intracranial aneurysms: Factors affecting the quality of mid-term aneurysm occlusion. Analysis in a prospective, multicenter series of patients (CLARITY). *AJNR Am J Neuroradiol*, 2012; 33: 1475-1480.


Tables

Table 1 - Clinical and anatomical results in the series of the literature

	Pierot [12]	Lubicz [13]	Pierot [14]	Papagiannaki [15]
Centres	3	1	5	11
Patients/Aneurysms	20/21	18/19	33/34	83/85
Ruptured	4.8 %	21.1 %	5.9 %	4.7 %
MCA	38.1 %	73.7 %	100.0 %	56.5 %
BA	23.8 %	10.5 %	0. %	21.2 %
Acom	19.0 %	10.5 %	0.0 %	12.9 %
ICA	19.0 %	5.3 %	0.0 %	9.4 %
Neck \geq 4mm	66.7 %	100.0 %	88.2 %	85.9 %
Feasibility	100.0 %	95.0 %	97.1 %	92.8 %
Add. Treatment	23.8 %	10.5 %	12.1 %	11.4 %
Morbidity (mRS>2)	0.0 %	5.3 %	3.1 %	1.3 %
Mortality	0.0 %	0.0 %	0.0 %	0.0 %
Adequate Occl. (TO+NR)	80.0 %	92.9 %	83.3 %	92.3 %

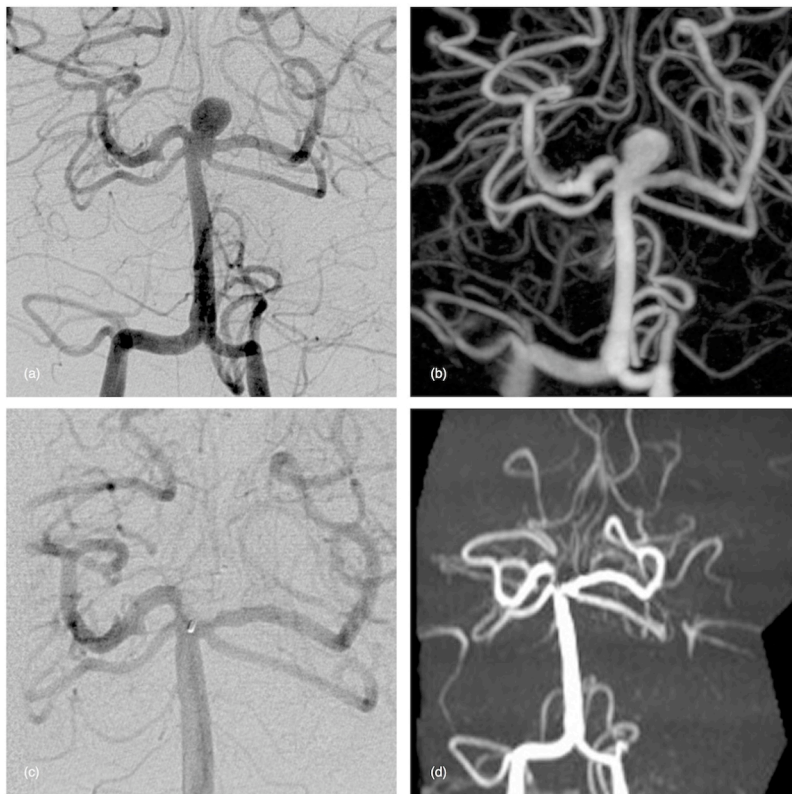
Figures

Figure 1 - The WEB family



(a) WEB-DL device. (b) WEB-SL device. (c) WEB-SLS device.

Figure 2 - Unruptured basilar tip aneurysm in a 60-year old female treated with a WEB-DL device.

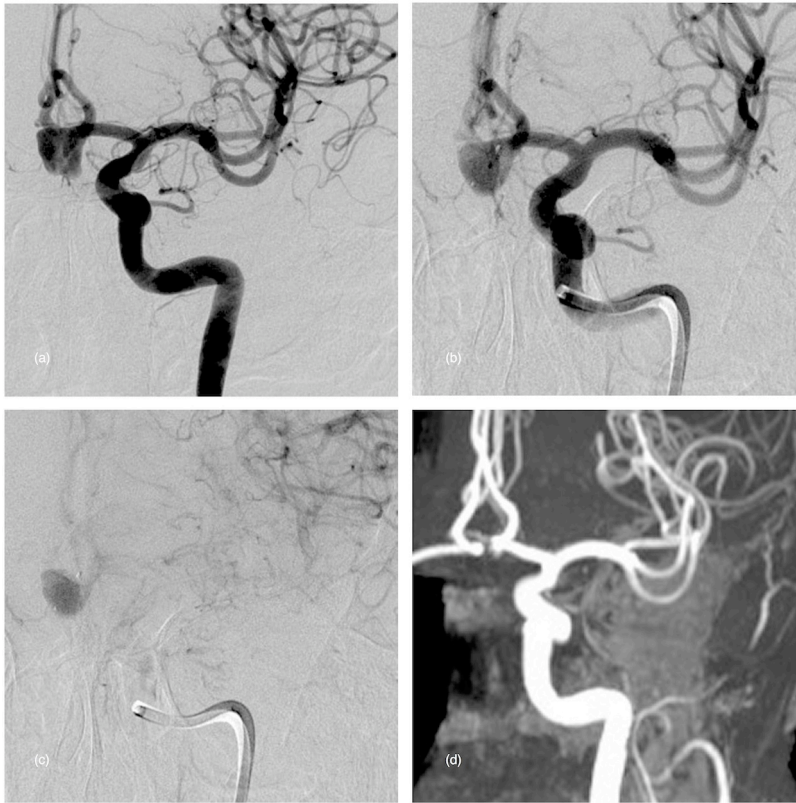


(a) & (b) Frontal preoperative DSA (2D and 3D) showing a wide-neck basilar aneurysm.

(c) Post-operative DSA (frontal view) after WEB-DL deployment and detachment showing no more flow in the device and the aneurysm.

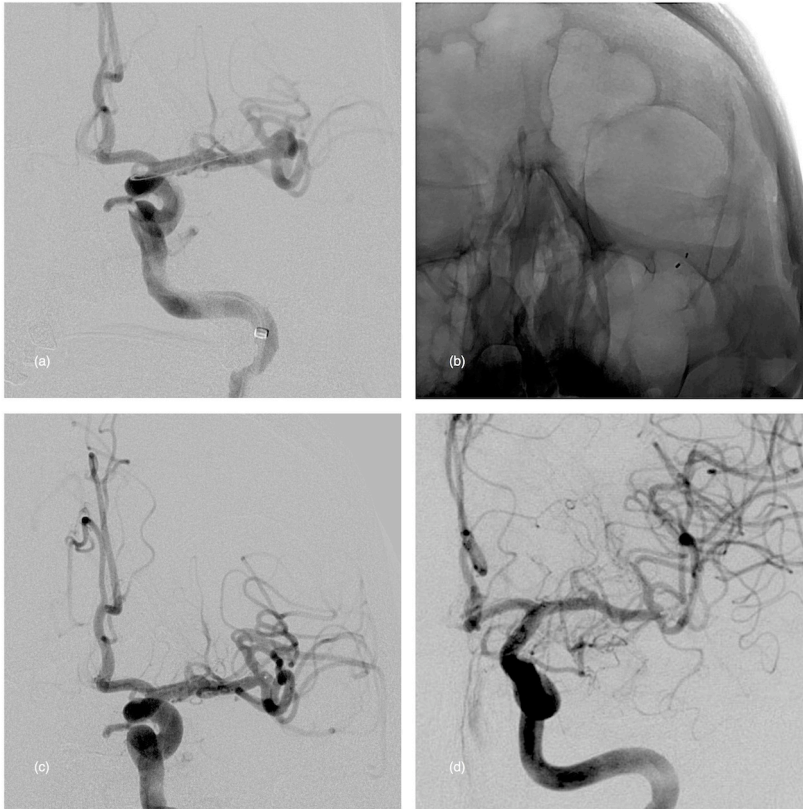
(d) 48-hour MRA (frontal view, 3D-TOF) showing the complete occlusion of the aneurysm. Both P1 segments are patent.

Figure 3 - Unruptured Acom aneurysm in a 60-year old male treated with a WEB-SLS device.



- (a) Preoperative DSA (frontal view) showing the aneurysm.
- (b) & (c) Postoperative DSA (frontal view, early and late phases) showing a flow stagnation in the device and the aneurysm.
- (d) 48-hour (frontal view, 3D-TOF) showing the complete occlusion of the aneurysm.

Figure 4 - Unruptured MCA aneurysm in a 45-year old female.



- (a) Preoperative DSA (working view) showing the wide-neck MCA aneurysm.
 (b) & (c) Postoperative DSA (working view, unabstracted and subtracted) showing the markers of the device and no residual flow in the device and the aneurysm.
 (d) One-year DSA (frontal view) showing the complete occlusion of the aneurysm.